



Patient

NHS No

D.O.B.

Patient Ref

Reason

Varicose vein

Outcome

DVT negative, Poor images, patient habitus, Incompetence

	Right		Left	
Deep Veins	Patency	Competency	Patency	Competency
Common Iliac Vein				
External Iliac Vein				
Internal Iliac Vein				
Common Femoral Vein	Widely Patent	Competent		
Profunda Vein	Widely Patent	Competent		
Superficial Femoral Vein	Patent	Competent		
Popliteal Vein	Widely Patent	Competent		
Posterior Tibial Vein	Patent	Competent		
Anterior Tibial Vein	Patent	Competent		
Peroneal Vein	Patent	Competent		
Soleal Vein				
Gastrocnemius	Widely Patent	Competent		
Superficial Veins				
Saphenofemoral Junction	Widely Patent	Competent		
L Saphenous Vein Above	Widely Patent	Competent		
L Saphenous Vein Below	see notes	Isolated Incompetence		
Vein of Giacomini	Not Identified			
Saphenopopiteal Junction	Widely Patent	Competent		
S Saphenous Vein	Widely Patent	Competent		
Evidence of D.V.T.				
Above the knee	No			
Popliteal	No			
Below the knee	No			

Notes**RIGHT LOWER LIMB VENOUS DUPLEX ASSESSMENT**

Difficult assessment due to patient's body habitus, depth of vessels and sub-optimal image resolution. Iliac veins not viewed. Flow in the common femoral vein is phasic with respiration and a normal response on Valsalva manoeuvre, suggesting proximal vein patency. All visualised deep veins appear widely patent / patent and competent with no evidence of previous DVT.

All measurements are proximal to the medial malleolus unless otherwise stated.

SFJ is widely patent and competent. Long saphenous vein (LSV) is competent in the thigh. An incompetent perforator was noted in the proximal calf (~30cm), rendering the LSV incompetent in the prox-mid calf. Two incompetent branches noted at ~27cm, forming a small network of incompetent, superficial veins within this section of the calf. LSV was not identified within the distal calf. No visible

Assessed by

Lukasz Koprowski

Checked by



Patient

NHS No

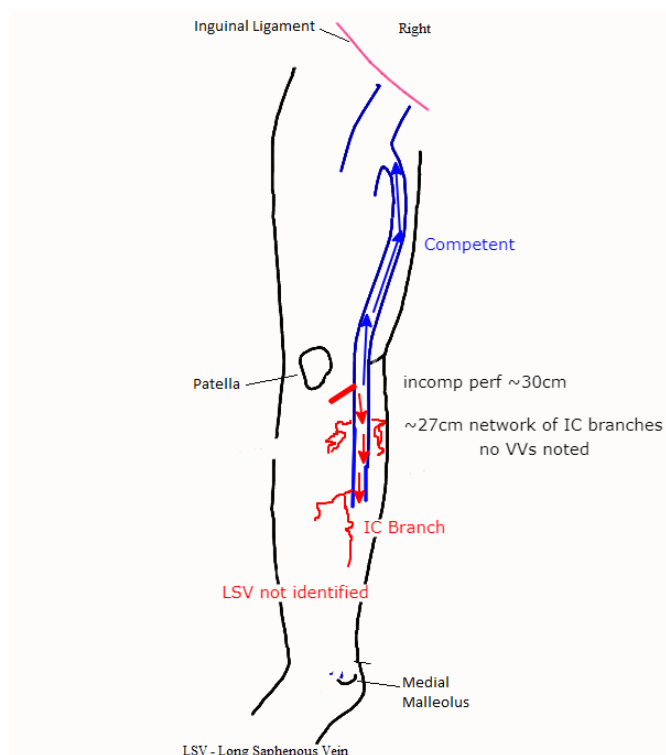
D.O.B.

Patient Ref

varicosities noted at this time.

Sapheno-popliteal junction (SPJ) and short saphenous vein (SSV) appear to be competent.

Transverse (AP) dimensions of LSV: Proximal / mid calf - 0.4cm.



Assessed by

Lukasz Koprowski

Checked by